

# Cesarean section in dromedary camels under field conditions in United Arab Emirates

Suhel Anwar<sup>1</sup>, Mazhar Iqbal Siddiqui<sup>2</sup> and G N Purohit<sup>3\*</sup>

<sup>1</sup>Al-Qattara Veterinary Hospital, Al-Ain, UAE

<sup>2</sup>Central veterinary hospital Al- Watba, Abu Dhabi, UAE

<sup>3</sup>Department of Veterinary Gynaecology and Obstetrics, College of Veterinary and Animal Science, Rajasthan University of Veterinary and Animal Sciences Bikaner, Rajasthan, India

\* Corresponding Author: gnpobs@gmail.com

Paper No. 8: MS Received: 19 May, 2012 MS Accepted: 12 September, 2012

## Abstract

In this study we analyze the causes of dystocia in 17 camels for which cesarean section had to be performed at the farmer's doorstep, along with the outcome of such surgeries. Maternal causes of dystocia were common (58.82%) indications for the surgery compared to the fetal causes (41.18%). The maternal causes included uterine torsion (17.64%), cervical dilation failure (11.76%), narrow birth canal (11.76%) due to pelvic fracture or dam's immaturity, uterine rupture (5.88%), uterine prolapse (5.88%) and vaginal rupture (5.88%). The fetal causes included uncorrectable fetal malpostures (29.41%), oversized fetus (5.88%) and schistosoma reflexus (5.88%) monster. Only 35.29% of the calves could be delivered alive and the calf viability depended upon the time of referral (6h-10days) after the onset of 2<sup>nd</sup> stage of labor. The proportion of male and female calves delivered was 58.82 and 41.18% respectively. With sufficient peri-operative care the dam survival was high (70.58%) and only 29.41% dams died due to severe blood loss or peritonitis. The common postoperative complications were edema at the operative site, minor wound dehiscence and subsequent herniation. It was concluded that

maternal dystocia requires more cesarean sections in camel and with sufficient care and early intervention fetal and dam survival can be high even when the surgery is performed at the farmer's doorstep.

©2012 New Delhi Publishers. All rights reserved

**Keywords:** Camel, cesarean, dystocia, schistosoma reflexus, uterine torsion.

## Introduction

Cesarean section is an emergency surgery performed when manual vaginal delivery is not possible. This is one of the challenging surgeries performed on the farm as the surgeon has less control over the patient, environmental contamination, and lesser availability of assistance (Newman, 2008). The goal of cesarean section is survival of mother, survival of calf and maintenance of future fertility (Vermunt, 2008). Successful outcome of this procedure

depends upon the prompt decision taken to perform cesarean section, condition of dam, calf viability at the time of surgery, patient and surgeon preparation, surgical techniques, skills and speed of surgeon, concomitant use of antibiotics and anti inflammatory drugs along with correction of dehydration (Newman and Anderson, 2005 and Anderson, 2010). Cesarean section in dromedary camel is often indicated when there is sufficient delay in presentation as beyond 48 hr of onset of 2<sup>nd</sup> stage of labor fetotomy is less rewarding (Purohit *et al.*, 2011) although the camel fetus survives dystocia better (Arthur *et al.*, 1999). The other reasons for performing cesarean sections are faulty fetal disposition, narrow contracted birth canal and fetal emphysema, fetal monster (Purohit, 2012) narrow maternal pelvis (Sharma and Pareek, 1970) uterine torsion and schistosoma reflexus (Elias, 1991).

During a three year period (2010-2012) we performed seventeen cesarean sections on camels in an open environment. The aim of this study was to evaluate the various causes and outcomes of this procedure under field conditions.

## **Material and Methods**

### **1. Cases and animals**

All cases were reported in surgery section of central veterinary hospital Al Qattara, Al-Ain United Arab Emirates through the field veterinarians between January 2010 and April 2012. Mobile veterinary surgery unit immediately

rushed towards the site and all the cesarean sections were carried out on the farms. The female dromedary camels that underwent surgery were between 6 to 18 years old. All cases in this study were previously handled and delay in presentation was created by unsuccessful attempts of delivery per vaginam by other veterinarians. Some cases were even presented after partial fetotomy.

### **2. Preoperative preparation**

Cesarean section is mostly considered as an emergency surgery thus preoperative fasting is not possible in camels. It is necessary to care for general condition of the animal before attempting to perform a cesarean section. The exhausted and dehydrated camels under poor condition of general health were first treated with fluid replacement, antibiotics and corticosteroids as required.

### **3. Restraint and anesthesia**

Camels were restrained in sternal recumbency before premedication. Both the fore limbs and hind limbs were tied separately with cotton rope as described previously (Gahlot, 2000). Xylazine (0.25mg/kg) was administered intravenously along with local infiltration (60-100 ml of 2 % lignocaine hydrochloride) in the form of inverted "L" block at the flank region. As soon as the animals were sedated they were secured in right lateral recumbent position.

### **4. Surgical technique**

A left flank laparohysterotomy was

performed as per previously described procedures (Elias, 1991; Purohit *et al.*, 2000 and Anwar and Purohit, 2012). Briefly, a wide surgical field over the left flank was prepared for aseptic surgery by clipping, shaving and washing the entire area with soap and water from below the transverse processes dorsally, to just above the milk vein ventrally, and from the last rib to the hind leg, level with the tuber coxae. Thereafter, 7.5 % povidone iodine was applied, followed by surgical spirit. A skin incision (30-40 cm long) in the middle of Para lumbar fossa starting from a point 6-8 cm below lumbar transverse process, 5 fingers posterior and parallel to the last rib was given. Further dissection through sub cutis, muscularis and peritoneum was carried out taking care of the spleen lying underneath. The uterus was grasped over a fetal extremity and brought to the operative site and packed with sterile drapes. The uterus was incised in the area of lower blood supply and the fetus was removed with the help of assistance. The fetal membranes were removed at the time of surgery if they were lying free within the uterus or could be readily detached, otherwise, they were returned to the uterine lumen and any protruding tags trimmed. The uterus was thoroughly washed with 1-1.5 liters of sterile saline before closure with single layer of Utrecht sutures using chromic catgut no. 3. The uterus was replaced back in the abdominal cavity ensuring that there was no torsion of the genital tract. The abdominal cavity was inspected for large blood and fibrin clots, which were

carefully scooped out by hand. Water soluble antibiotic solution of penicillin streptomycin (50-60 ml) was poured within the abdominal cavity. The peritoneum and muscle layers were closed using continuous lockstitch sutures using chromic catgut no. 4. The skin was closed with mattress sutures using sterile silk (USP no. 3). Extreme precaution was taken during closure of each layer which was washed with normal saline and antibiotics were instilled. Vulva was sutured with umbilical tape in cases where uterine prolapse was present previously or suspected post operatively.

### **5. Post operative care**

Oxytocin (20-40 IU) was injected intravenously soon after completion of surgery. Injection Penstrep (1 ml / 20 kg. b.wt.) was administered for 7 days along with injection Ketoprofen (15-20 ml) intravenously for 3-5 days. Ringer's lactate (3-5 liters) and 5 % dextrose with normal saline (3-5 liters) was infused daily as per requirement. Suture line was cleaned with 7.5% povidone iodine every day. Skin sutures were removed 3-4 week postoperatively depending upon the healing of the skin.

### **Results**

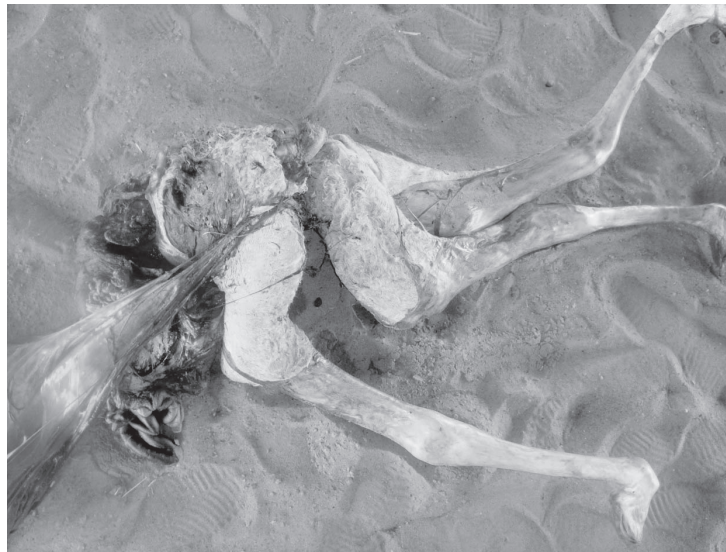
During the study period, cesarean section was performed on 17 dromedary camels suffering from dystocia (Table 1). Ten of these cases (58.82%) were caused by maternal form and seven cases (41.18%) were caused by fetal form of dystocia. Amongst the maternal causes three cases

(17.64%) were presented with right uterine torsion in which rolling of the dam was unsuccessful, whereas one case of uterine rupture (5.88%) was diagnosed in which the fetus was displaced in the abdominal cavity of dam and another case was a prolapse of large intestine through a tear in vaginal wall (5.88%). These genital ruptures developed during attempts of assisted delivery. The prolapsed portion of intestine was reduced after cesarean section and the vaginal tear was repaired. Prolapse of non gravid horn (5.88%) was seen in one case. The other maternal causes noticed were failure of cervical dilation (2 cases; 11.76%), and in 2 cases (11.76%) a narrow birth canal was observed due to pelvic fracture or maternal immaturity.

The proportion of fetal causes included five cases (29.41%) of fetal malpostures and one case each of oversized fetus (5.88%) and schistosoma reflexus (5.88%) (Figure 1).

The commonest fetal malpostures was deviation of head, neck and limbs (17.64%) whereas 11.76% of fetuses were found in posterior presentation at the time of cesarean section.

Only six calves were born live at time of cesarean section, out of which one calf died on the 7<sup>th</sup> postoperative day due to severe diarrhea. A high proportion of calves delivered were male (58.82%) whereas 41.18% of the calves delivered were female.



**Fig 1:** A schistosoma reflexus fetus removed by cesarean section in a camel. The head and one limb of the fetus were removed prior to cesarean.

The most common postoperative complications observed were fluid accumulation at suture site in four camels on 3<sup>rd</sup> post operative day which was corrected by needle aspiration and intravenous administration of dexamethasone. Such treatment responded in two camels but in the rest two camels abscess and pus formation was noticed. Other complications were development of hernia near suture line in three cases. The time interval for post cesarean hernia formation was recorded from 1.5 month to 4 month (Figure 2).

Four camels died after cesarean section from 1<sup>st</sup> to 5<sup>th</sup> post operative day probably due to severe blood loss and development of peritonitis. The camels that died had poor general condition at the time of presentation, one of such camel was operated 10 days later after onset of 2<sup>nd</sup> stage of labor. The fetus was dead and putrefied in this camel so the prognosis was guarded. Other camels had uneventful recovery without any complications. Skin sutures were removed as required between 20 to 36 days.



**Fig 2:** A female camel that developed post cesarean hernia 4 months after the operation.

Table 1: Analysis of causes and outcome of cesarean sections performed at farmer's doorstep in camels

Case no.	Cause of dystocia	Time since arrival of surgeon	Fate of calf	Sex of calf	Post-operative complication and abscess formation	Fate of dam
1	Posterior presentation	8 hr	dead	Male		Survived
2	Right uterine torsion	5 days	live	Male	None	Died postoperative day 5 <sup>th</sup>
3	360° / recumbent dam vaginal rupture with evisceration of large intestine	10 hr	dead	Female	None	Survived
4	Failure of cervical dilation	10 days	dead	Female	none	Died postoperative 3hr
5	Failure of cervical dilation	3 days	dead	Female	Suture infection/minor wound dehiscence /post cesarean hernia (3 months later)	Survived
6	Right uterine torsion 180°	28 hr	live	Male	None	Survived
7	Uterine rupture with descend of fetus in abdominal cavity	6 hr	dead	Male	None	Died postoperative 8hr
8	Posterior presentation	26 hr	dead	Male	Edema (3 <sup>rd</sup> postoperative day)	Survived
9	Neck and limb deviation	6 hr	live	Male	None	Survived
10	Schistosoma reflexus	52 hr	dead	Male	None	Died postoperative day 2 <sup>nd</sup>
11	Pro lapse of non gravid uterine horn prior to delivery	22 hr	dead	Male	None	Survived
12	Uterine inertia /recumbent dam due to pelvic fracture	16 hr	live	Female	None	Euthanized
13	Innate narrow pelvis	8 hr	dead	Female	Suture infection (8 <sup>th</sup> postoperative day)	Survived
14	Right uterine torsion 180°	15 hr	live	Female	None	Survived
15	Head and neck deviation with bilateral carpal flexion	12 hr	dead	Male	none/hernia (4 month later)	Survived
16	Edematous and oversized fetus	24 hr	dead	Male	None/hernia (1.5 months later)	Survived
17	Neck flexion	6 hr	live	Female	None	Survived

## Discussion

Most published data on cesarean section in camels is limited to individual case reports (Petris, 1956; Rathore, 1962; Sharma and Pareek, 1970; Purohit *et al.*, 1985; Elias, 1991; Purohit *et al.*, 2000 and Van Straten, 2000). Purohit *et al.*, 2011 reported causes of dystocia and outcome of cesarean section in six camels. The present study showed that cesarean section is required more often to correct maternal causes of dystocia. In the present report the estimated time between animal keepers noticing the symptoms of labor and arrival of surgeon was long enough (average 39.47 hr, range 6-240 h). This delay was due to inability of many animal keepers to recognize the symptoms of delivery and seek veterinary help. Moreover, delay by field veterinarians in taking decision for cesarean section was another cause.

Many previous studies mention that fetal dystocia is more common in camel as compared to maternal dystocia (Arthur and Al-Rahim, 1982; Arthur *et al.*, 1985; Arthur, 1992; Van Straten, 2000; Al-Eknah, 2001; Purohit *et al.*, 2011 and Purohit, 2012) whereas in our study maternal dystocia was common as compared to fetal dystocia. The difference between our study and previous studies are because, in the present study all the cases were those that could not be corrected by mutation and fetotomy, and dystocia of fetal origin were mostly corrected by mutation and fetotomy.

Rolling attempts in camels with uterine

torsion were unsuccessful and cesarean section was the choice of treatment. The correction of uterine torsion by rolling is not readily feasible in camel because of its large size and enormous resistance that would probably be exerted by the animal (Purohit, 2012). Most other studies also suggest cesarean section in case of uterine torsion in camels (Petris, 1956; Nigam *et al.*, 1977; Tibary *et al.*, 2008; Purohit *et al.*, 2011 and Purohit, 2012). Uterine rupture and vaginal tears found near parturition in the current study are similar to previous reports in camel (Van Straten, 2000) and in horses (Sutter *et al.*, 2003). Camels with live malpostured calves are at high risk of uterine rupture and vaginal tear during mutation operations due to the long fetal extremities.

Prolapse of non gravid horn of uterus before parturition is not a common finding (Anwar and Purohit, 2012) and it is usually seen as a complication of parturition, especially subsequent to excessive obstetric manipulation (Tibary and Anouassi, 1997). We have previously recorded a similar case (Anwar and Purohit, 2012). Cervical dilation failure found in two camels during the present study has rarely been reported in camel (Vyas *et al.*, 1999). Similar findings have been observed for three alpacas that underwent cesarean section (Saltet *et al.*, 2000). Secondary uterine inertia with recumbent dam due to pelvic fracture reported in the present study is a rare finding and only possible when a fetus cannot be delivered by efforts of the dam because of fetal

maldisposition (Purohit, 2012). Narrow pelvises in immature dam due to untimely breeding of females require cesarean section (Purohit, 2012).

Posterior presentations required cesarean section in this study. It has been previously mentioned that in posterior presentations if judicious traction by four attendants' does not succeed, the fetus must be removed by cesarean section or fetotomy (Arthur *et al.*, 1999). In uncorrectable fetal malpostures, oversized fetus and fetal monstrosity cesarean section was preferred as suggested previously (Van Straten, 2000 and Purohit *et al.*, 2011).

The use of xylazine as a sedative administered by intravenous route along with local infiltration anesthesia as suggested previously (Sharma *et al.*, 1982; Purohit *et al.*, 1985; Purohit *et al.*, 1989 and Purohit *et al.*, 2000) evidenced good anesthesia for cesarean in camels. The dose of xylazine suggested for camels is 0.25 mg/Kg (Bolbol *et al.*, 1980; Sharma *et al.*, 1982 and Ali *et al.*, 1989). Camels could be safely sedated at this dose of xylazine. The operative site used in this study was similar to previous reports (Sharma and Pareek, 1970; Elias, 1991; Purohit *et al.*, 2000; and Purohit, 2012) and the operative procedure could be completed without any difficulty. Although a few reports mention that the oblique ventro-lateral site is better for cesarean section in camels (Purohit *et al.*, 2011 and Purohit, 2012) due to dangers of accidental cutting of the spleen (Purohit *et al.*,

2011) however, with careful operative procedures such dangers were not observed during the present study.

The post operative complications in the present study were development of edema at the operative site on 3<sup>rd</sup> postoperative day in two camels whereas in one camel there was abscess formation. In two camels suture infection was found, whereas minor wound dehiscence and subsequent abdominal herniation three months later was observed in one camel. Herniation without any previous postoperative complication was seen in two camels at 1.5 and 4 month respectively. The occurrence of post cesarean hernia formation at the operative site has been previously reported (Purohit *et al.*, 1989 and Purohit *et al.*, 2011). Edema at the operative site could be probably because of loose spaces between the muscle layers (Gahlot, 2000). Sutures were removed at 3-4 week in most camels. Suture removal in camels is suggested at 2 weeks (Tibary and Anouassi, 2000).

Four camels died within 1<sup>st</sup> to 5<sup>th</sup> postoperative day and one camel was slaughtered on the day of cesarean section. Camels died in our study probably because of development of peritonitis or severe bleeding as also recorded previously (Sloss and Dufty, 1977 and Purohit *et al.*, 2011). In this study a high proportion (70.58%) of camels recovered after cesarean section performed in open areas probably because of good peri-operative care, correction of dehydration and sufficient



use of antibiotics during surgery. These approaches can help in minimizing adhesions and development of peritonitis. Adequate care to prevent the contamination of abdominal cavity, adequate in folding of uterine incision to prevent leakage, timely completion of procedure, anti inflammatory and high doses of antibiotics during post operative period are likely key elements that contribute high dam survival.

From the results of this study it was concluded that maternal dystocia requires more cesarean sections in camel and with sufficient care and early intervention fetal and dam survival can be high even when the surgery is performed at the farmer's doorstep.

## References

- Al-Eknah MM. 2001. Camels In: Noakes DA, Parkinson TJ, England GCW (Eds) Arthur's Veterinary Reproduction and Obstetrics. 8th ed. WB Saunders London, 781-788.
- Ali BH, El Sanhoury AA. and Musa BE. 1989. Some clinical, haematological and biochemical effects of four tranquilizers in camels (*Camelus dromedarius*). *Revue Elev Med Vet Pays Trop.* **42**:13-17.
- Anderson D. 2010. Cesarean section in alpacas and llamas: 25 cases (2000-2008). *Proc 26th Congr World Assoc Buiatrics*, Santiago de Chile.
- Anwar S. and Purohit GN. 2012. An unusual dystocia in dromedary camel with uterine prolapse and its surgical correction. *J Camelid Sci.* **5**:118-121.
- Arthur GH. and Al-Rahim AT. 1982. Aspects of reproduction in the female camel (*Camelus Dromedarius*) in Saudi Arabia. *Vet Med Rev.* **1**:83-88.
- Arthur GH, Rahim ATA. and Al Hindi AS. 1985. Reproduction and genital diseases of the camel. *Br Vet J.* **141**:650-659.
- Arthur GH. 1992. An overview of reproduction in the camelids. In: *Proc 1st Int. Camel Conf, Dubai*, 109-113.
- Arthur GH, Noakes DE, Pearson H. and Parkinson TJ. 1999. Reproduction in the camel. In: Arthur GH, Noakes DE, Pearson H. and Parkinson TJ. Eds., *Veterinary Reproduction and Obstetrics*, WB Saunders, London, 659-666.
- Bolbol AE, Hassanein A. and Ibrahim H. 1980. Some investigations in the camel after sedation with Rompun (xylazine). *Veterinar Medizinische Nachrichten.* **1**:55-60.
- Elias E. 1991. Left ventrolateral cesarean section in three dromedary camels (*Camelus dromedarius*). *Vet Surg.* **20**: 323-325.
- Gahlot TK. 2000. Surgery of dromedary camel. In: Gahlot TK, Singh J ed. *Selected Topics on Camelids*. Camelid Publishers India, pp. 286-356.
- Newman KD, Anderson DE. 2005. Cesarean section in cows. *Vet Clin North Am Food Anim Pract.* **21**:73-100.
- Newman KD. 2008. Bovine cesarean section in the field. *Vet Clin North Am Food Anim Pract.* **24**:273-293.
- Nigam JM, Gupta RC, Khar SK. and Shetty BR. 1977. Torsion of the uterus in a camel. *The Haryana Vet.* **16**: 33-36.
- Petris MA. 1956. Cesarean operation in camels. *Vet Rec.* **68**: 374-376.
- Purohit GN, Mehta JS, Garg N, Vyas K, Gupta AK, Pareek PK. and Sharma SS. 2000. Caesarean section in a dromedary camel: a case report. *Indian J Anim Reprod.* **1**: 76-77.
- Purohit GN, Mehta JS, Dholpuria S, Barolia Y, Kumar P, Shekher C. and Yadav SP. 2011. Dystocia in dromedary camels: handling and outcome of fourteen cases. *Theriogenology Insight* **1**:15-23.

- Purohit GN. 2012. Dystocia in camelids: The causes and approaches of management. *Open J Anim Sci.* **2**: 99-105.
- Purohit NR, Chauhan DS, Purohit RK. and Chaudhary RJ. 1985. Cesarean section in a camel. *Agric Practice.* **26**: 28-29.
- Purohit NR, Chauhan DS. and Chaudhary RJ. 1989. Post cesarean ventral hernia in two camels. *Br Vet J.* **145**:294.
- Rathore SS. 1962. Cesarean operation in camels. *Indian Vet J.* **39**: 42-44.
- Saltet J, Dart AJ, Dart CM. and Hodgson DR. 2000. Ventral midline cesarean section for dystocia secondary to failure to dilate the cervix in three alpacas. *Austr Vet J.* **78**: 326-328.
- Sharma DK. and Pareek PK. 1970. Clinical communication: caesarean section in a camel. *Ceylon Vet J.* **18**:7-9.
- Sharma DK, Behl SM and Khanna BM. 1982. Use of xylazine as anesthetic in cesarean in a camel. *Haryana Vet.* **21**: 50-51.
- Sloss V. and Dufty JH. 1977. Elective cesarean operation in Hereford cattle. *Aust Vet J.* **53**:420-24.
- Sutter WW, Hoppe RM, Embertson R. and Frazer GS. 2003. Diagnosis and Surgical Treatment of Uterine Lacerations in Mares (33 Cases) *49<sup>th</sup> Ann Conven Am Assoc Equine Pract,* New Orleans, Louisiana, [ivis.org](http://ivis.org). (Nov 2003).
- Tibary A. and Anouassi A. 1997. Obstetrics and neonatal care. In: Tibary A. Ed. *Theriogenology in Camelidae*. Abu Dhabi Printing Press, Mina.
- Tibary A. and Anouassi A. 2000. Surgery of the reproductive tract in camels. In: Skidmore JA. and Adams GP. Eds., *Recent Advances in Camelid Reproduction*. International Veterinary Information Service. [www.ivis.org](http://www.ivis.org). A.1008.1100.
- Tibary A, Rodriguez JS, Anouassi A. and Walker P. 2008. Management of dystocia in camelids. *Proc 41st Ann Conf AmAssoc Bovine Pract,* Charlotte, 25-27 September. 166-176.
- Van Straten M. 2000. Periparturient conditions affecting camels (*Camelus dromedarius*) in Israel and their treatments. *Revue Elev Med Vet Pays Trop.* **53**:101-104.
- Vermunt JJ. 2008. The Caesarean Operation in Cattle: a Review *Iranian J Vet Surg Suppl:* 82-100.
- Vyas S, Sharma N, Bissa UK, Chirania BL. and Bishnoi BL. 1999. Effect of prostaglandin F2 alpha on induction of parturition in a she camel. *Indian J Anim Reprod.* **20**: 73.