



Incidence of Cystic Liver Caused by *Cysticercus fasciolaris* in Laboratory Rat

Saurabh Chawla^{*1} and Sarita Jena²

¹Animal Facility, National Institute of Science Education and Research, Bhubaneswar, INDIA

²Animal Facility, Institute of Life Sciences, Bhubaneswar, INDIA

*Corresponding author: S Chawla; Email: drchawlasaurabh@gmail.com

Received: 01 November, 2014

Accepted: 30 April, 2015

ABSTRACT

Herein we are reporting about an incidence of *Cysticercus fasciolaris* infestation in a male and female Sprague Dawley housed for experimental purpose. The clinical finding includes anorexia and dullness. Post mortem examination of both the animals revealed cystic liver with irregular lump of hard tissue attached to left lateral lobe of liver in male rat. A thin, pale white segmented larva with distinct head was found lodged inside the cyst in both the animals. Based upon the morphological features, the larva was identified to be intermediate stage of *Taenia taeniaeformis* which is a tapeworm of cat with rodents acting as intermediate host. Most of the rodent facilities do not screen laboratory animals for presence of this parasite in regular health monitoring procedures. The findings are important due to impact of this parasite on animal health, research studies and sporadic zoonotic potential.

Keywords: Rat, cystic liver, tapeworm

Laboratory animals often get exposed to variety of parasitic diseases due to breach in biosecurity measures. Unwanted parasitic diseases may get introduced into experimental rodent causing deviation in animal health and research implications.

Taenia taeniaeformis is a common parasite of cat and its intermediate stage called *Cysticercus fasciolaris* is generally found to infect wild rat (Baker, 2007). *Cysticercus fasciolaris* can be identified based upon morphological features and is generally lodged in liver parenchyma of rodents (Sinniah *et al.*, 2014). The infestation of laboratory rat with this parasite compromises the health status of experimental animals, may have vast research implications and also carry a zoonotic risk for animal care staff (Miyazaki, 1991; Easterbrook *et al.*, 2007). *T. taeniaeformis* is although cosmopolitan in distribution but its presence in laboratory animals is a rare occurrence (Miyazaki, 1991; Singla *et al.*, 2008). Wild and domestic cats of family felidae act as definitive hosts for this parasite which passes embryonated eggs in their feces which in turn may be ingested by rats. These eggs hatch in small intestine of rats and embryos are passed through portal circulation to liver, where they develop into infective

stage. The infection is carried and transmitted through rat to other feline carnivores (Soulsby, 2005; Baker, 2007).

The source of infection in laboratory animals may through contamination of feed, bedding and water with cat faeces carrying embryonated eggs during routine husbandry operations, although a rare occurrence in a well-established animal facilities. Another possibility, which is less thought of, is entry of infection during transportation of laboratory rodents between institutions. Organized animal facilities generally do not include testing of this parasite during routine quarantine and health monitoring programme. Here in this study we report accidental occurrence and post mortem findings of *Cysticercus fasciolaris*, the metacestode stage of tapeworm *Taenia taeniaeformis* in laboratory rat.

Male and female Sprague-Dawley rats, housed in autoclaved polysulfonate cages with corncob bedding, pellet feed and water bottles, were reported to be anorectic and dull, as observed by the animal care staff personnel. The affected rats were retired breeders and purchased from same source. Physical examination and palpation revealed enlarged abdomen with thick and firm lumpy



mass in male rat, however female counterpart did not reveal any abnormal findings. The animals were submitted for necropsy to arrive at a diagnosis. Animals were euthanized with intra peritoneal injection of Thiopentone sodium @ 150 mg/kg body weight. At the time of death male and female rat were of 12 months age, weighing 562 g and 402 g respectively. The liver showing pathologic lesions was removed and collected in petridish, which was further dissected out to reveal encapsulated cyst and larvae. The morphological analysis of adult larvae was done as described by Soulsby (2005) and Baker (2007). Animals used in study were housed in a well ventilated controlled environment. All the procedures were carried out as per CPCSEA (Committee for Purpose of Control and Supervision of Experiments on Animals) norms.

At necropsy the abdominal viscera of male rat revealed big thick irregular lump of hard tissue attached to left lateral lobe of liver and extending to left upper quadrant of peritoneal cavity (Fig.1). Another thick irregular lump of tissue 4 cm in diameter was attached to right medial

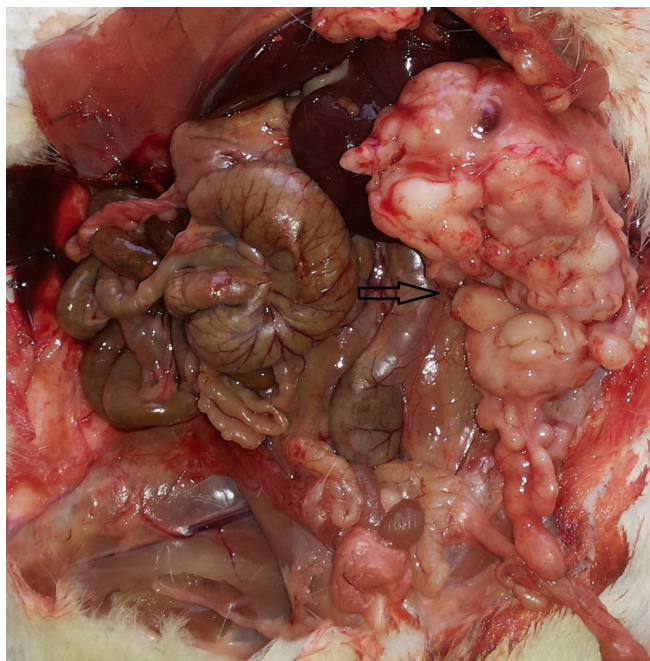


Figure 1. Lump of hard tissue attached to liver, extending to left upper quadrant of peritoneal cavity in male rat

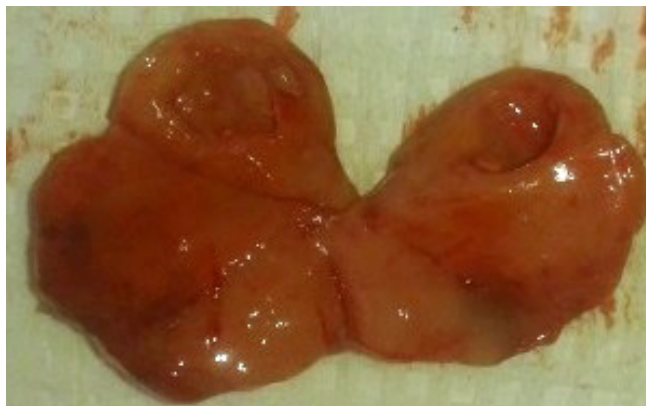

Figure 2. Encapsulated cyst dissected out from liver

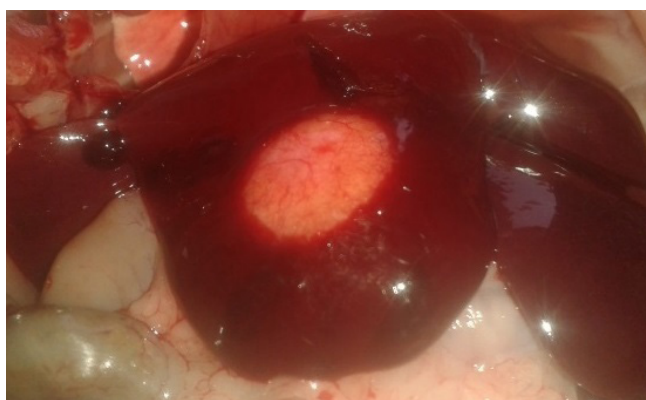

Figure 3. Cyst with irregular margins on the surface of liver in female rat

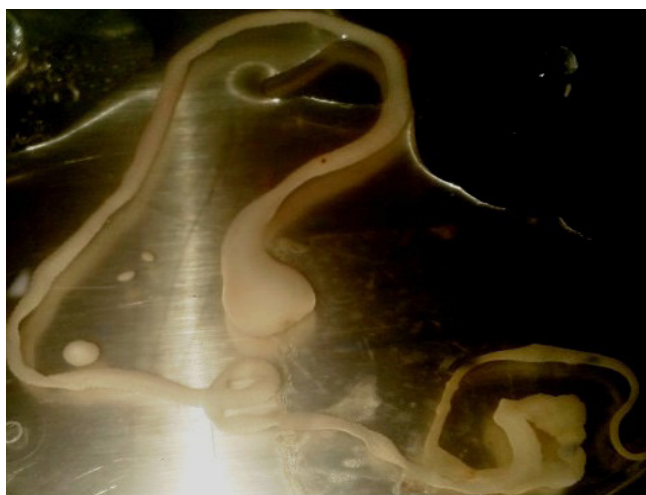

Figure 4 *Cysticercus fasciolaris* larvae dissected out from cyst in liver of female rat.

lobe of liver. The tissue was dissected out and cut to reveal encapsulated cysts, size of a pea with thick pale white fluid (Fig.2). Exploration of these cysts revealed thin, opaque, pale white, segmented, flat, elongated tape like larvae with distinct head measuring 15 cm in length.

Necropsy of female rat revealed a thin walled, pale white oval cyst with irregular margins on the surface of right medial lobe measuring 1.4 cm in diameter (Fig.3). On cut section the cyst was filled with thick white colored fluid with a thin, opaque, pale white, segmented, flat, elongated tape like larvae with distinct head measuring 61 cm in length and bladder like structure at distal end (Fig.4).

The morphological appearance of larvae (*Cysticercus fasciolaris*) was consistent with that of *Taenia taeniaeformis*. (Soulsby, 2005; Singla *et al.*, 2008).

The gross findings of rat revealed tumor like growth in liver and encapsulated cyst attached to liver. The intermediate stage of cat tape worm has been reported to cause similar lesions in wild as well as laboratory rodents (Hanes, 1995; Kumar *et al.*, 2006). Detection of these types of growth may sometimes be confused with spontaneous tumors common in laboratory animals. However detailed examination will reveal strobilocercus lodged inside the liver parenchyma. Also its diagnosis questions the biosecurity of animal facility as this worm spreads only through cat faeces. Another threat is the zoonotic potential of this tape worm, however occurrence is very rare (Ekanayake *et al.*, 1999). Moreover impact on research studies may be considerable if infected rats are used for experiment. Our facility follows strict bio exclusion procedures and all the animal consumables such as feed bedding and cages are autoclaved prior to use. The possible cause of exposure of laboratory rats to cat faeces/ tape worm egg may be from the street clothes worn by animal care personnel staff and researchers. The autoclaved Personal Protective Equipments (PPE) is donned upon street clothes and animals may get accidental exposure to infection during routine procedures. Another possibility of source of infection is exposure during transport of animals within institutes. The animals are brought to institute through air conditioned vehicle in commercially available transport boxes which may not guarantee exposure to

unwanted agents. This disease generally skips quarantine measures and infected animals gain entry into the facility.

The disease remains important due to its impact on animal health, research studies and sporadic zoonotic potential. Diagnosis of *Taenia taeniaeformis* larvae in laboratory rodents indicates breach in biosecurity and thus needs a deep investigation to stop future incidence.

We are thankful to animal facility attendants, Mr. Sarabita Sarangi and Mr. Biswajeet for help rendered.

Authors declare no competing financial interest.

REFERENCES

- Baker, D.G. 2007. Parasites of rats and mice. In: Flynn's parasites of laboratory animals, 2nd Ed, Blackwell publishing, Ames.
- Easterbrook, J. D., Kaplan, J. B., Vanasco, N. B., Reeves, W. K., Purcell, R. H., Kosoy, M. Y., Glass, G. E., Watson, J. and Klein S. L. 2007. A survey of zoonotic pathogens carried by Norway rat in Baltimore, Maryland, USA. *Epidemiol. Infect.*, **135**: 1192-1199.
- Ekanayake, S., Warnasuriya, N.D., Samarakoon, P.S., Abewickrama, H., Kuruppuarachchi, N.D. and Dissanaikie, A.S. 1999. An unusual 'infection' of a child in Sri Lanka with *Taenia taeniaeformis* of the cat. *Ann. Trop. Med. Parasitol.*, **93**(8): 869-873.
- Hanes, M.A. 1995. Fibrosarcomas in two rats arising from hepatic cysts of *Cysticercus fasciolaris*. *Vet. Pathol.*, **32**: 441-444.
- Kumar, J.M., Reddy, P.L., Aparna, V., Srinivas, G., Nagarajan, P., Venkatesan, R., Sreekumar, C. and Sesikaran, B. 2006. *Strobilocercus fasciolaris* infection with hepatic sarcoma and gastroenteropathy in a Wistar colony *Vet. Parasitol.*, **141**: 362-367.
- Miyazaki, I. 1991. Helminthic zoonoses. International Medical Foundation of Japan, Tokyo, pp.494.
- Singla, L. D., Singla, N., Parshad, V. R., Juyal, P. D. and Sood N. K. 2008. Rodents as reservoirs of parasites in India. *Integr. Zool.*, **3**: 21-26.
- Sinniah, B., Narasmiman, M., Habib. S. and Bei. O.G. 2014. Prevalence of *Calodium hepaticum* and *Cysticercus fasciolaris* in urban rats and their histopathological reaction in the livers. *J. Vet. Med.*, Article ID 172829.
- Soulsby, E.J.L. 2005. Cestodes. In: Helminths, arthropods and protozoa of domesticated animals, 7th Ed. Bailliere Tindall, Elsevier, India.

